

SYNCHRONIZED RF & HIFEM: HUMAN ADIPOCYTE APOPTOSIS HISTOLOGY

ADIPOCYTE APOPTOSIS INDUCED BY TREATMENT WITH SYNCHRONIZED RADIOFREQUENCY AND HIGH-INTENSITY FOCUSED ELECTROMAGNETIC PROCEDURE: HUMAN HISTOLOGIC ANALYSIS

David J. Goldberg M.D., JD¹, Karan Lal, M.D.²

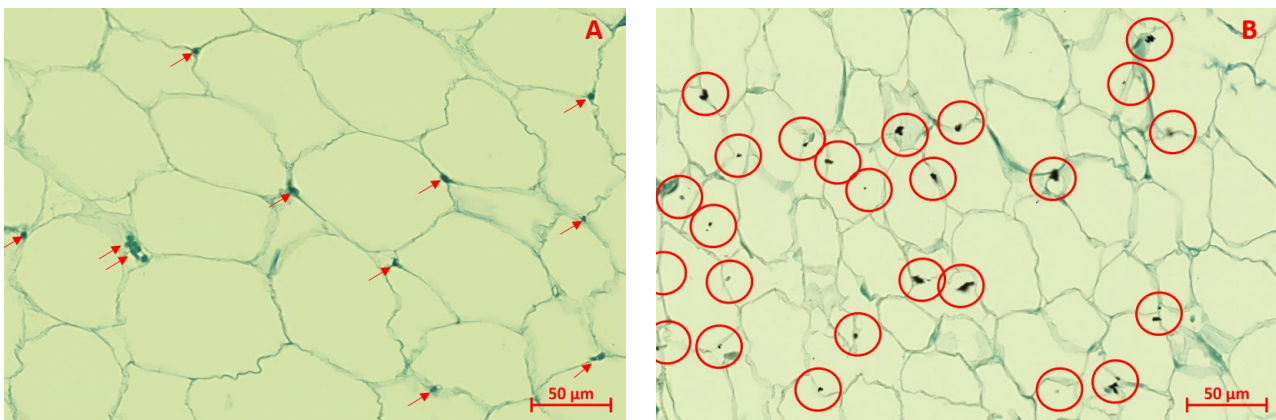
1. Icahn School of Medicine, New York, NY, USA

2. Skin Laser and Surgery Specialists, a Division of Schweiger Dermatology, Hackensack, NJ, USA

Presented at the Annual Meeting of the American Society for Dermatologic Surgery, 2022

HIGHLIGHTS

- 9 subjects (23-61 years, BMI = 24.6-34.7 kg/m², skin type I-V) were divided into the **active group (n=6, receiving one HIFEM+RF treatment)** and control group (n=3, sham treatment)
- **Punch biopsies** were obtained at **baseline, 8 hours, and 24 hours** after the treatment to measure the **levels of caspase-3**
- **Caspase-3** is an enzyme initiating the execution phase of apoptosis, as it is responsible for nucleus destruction and DNA fragmentation. **After caspase-3 activation, apoptosis is considered to be inevitable.**
- Immunohistochemical evaluation showed **significant activation of caspase-3** in the active group (p<0.001), indicating an elevated level of apoptosis.
- The apoptotic index increased on average from **7.3% to 47.01 ± 10.56% on average** (+540%)
- No significant change in the levels of apoptotic cells was observed in the control group



The left side (A) represents untreated adipose tissue with a healthy nucleus (red arrows), while the right side (B) represents adipose tissue 8 hours after the HIFEM+RF treatment with numerous apoptotic nuclei (red circles).